

# Wilms Tumor and Neuroblastoma

# Wilm's Tumor

- AKA: **Nephroblastoma**
- the most common intra-abdominal cancer in children.
- peak incidence is 2 to 3 years of age

# Biology

- **somatic mutations** restricted to tumor tissue  
(Majority of Cases)
- **germline mutations**

Sporadic:

Almost 97% of Wilms' tumors

Congenital:

Earlier age and the disease is frequently bilateral

# WT gene

- WT1 was originally considered to be a classic **tumor suppressor gene**, and the loss of both copies or mutations of this gene would lead to Wilms tumor development (Rauscher, 1993). Although this may be the case for some tumors, **only 20%** of patients with Wilms tumor have a mutation in the germline or in tumor tissue.
- WT2 gene has been linked to the **BWS**; excess growth at the cellular, organ (macroglossia, nephromegaly, hepatomegaly), or body segment (hemihypertrophy)
- WTX was found to be inactivated in up to one third of Wilms tumors (Rivera et al, 2007).

**Table 137-6.**

**Syndromes Associated with Development of Wilms Tumor**

SYNDROME	GENES	LOCUS	WILMS TUMOR RISK
WAGR	<i>WT1</i>	11p13	50%
Denys-Drash	<i>WT1</i>	11p13	50%
Frasier	<i>WT1</i>	11p13	5%-10%
Beckwith-Wiedemann	<i>WT2</i>	IGF-2, H19, p57, K1p2	5%-10%
Familial Wilms tumor	<i>FWT1</i> <i>FWT2</i>	17q21 19q13	30%
Perlman	Unknown		>20%
Mosaic variegated aneuploidy	<i>BUB1B</i>	15q15	>20%
Fanconi anemia D1	<i>BRCA2</i>	13q12.3	>20%
Simpson-Golabi-Behmel	<i>GPC3</i>	Xq26	10% (in males)
Li-Fraumeni	<i>TP53</i>	17p13	Low
Neurofibromatosis	<i>NF1</i>	17q11	Low
Sotos	<i>NSD1</i>	5q35	Low
Trisomy 18	Unknown	18	Low
Bloom	<i>BLM</i>	15q26	Low

# Presentation

- A palpable smooth abdominal mass often discovered incidentally.
- Abdominal pain
- Hematuria
- Hypertension → elevated plasma renin levels
- Rupture of the tumor with hemorrhage into the free peritoneal cavity can result in the occasional presentation of an **acute abdomen**.
- Extension of Wilms tumor into the renal vein and IVC can cause a **varicocele**, **hepatomegaly** due to hepatic vein obstruction, **ascites**, and **congestive heart failure**. less than 10% of patients with intracaval or atrial tumor extension
- assess for signs of associated Wilms tumor syndromes, such as aniridia, hemihypertrophy, and genitourinary anomalies.

# Imaging

- U/S as initial test
  - helpful in excluding intracaval tumor extension ( 4% of Wilms )
- CT scan or MRI (Chest, abdomen, pelvis)
  - detect local extension of tumor beyond the renal capsule or into regional lymph nodes
- PET no value

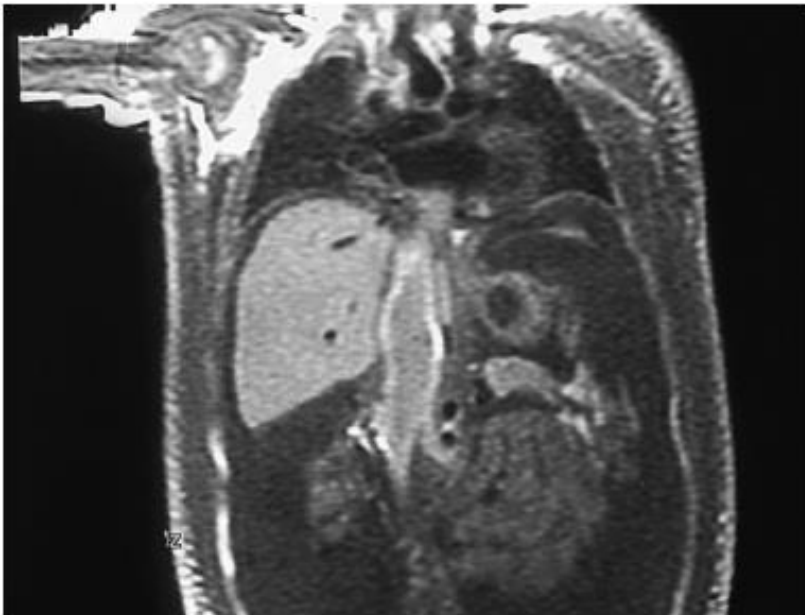


Figure 137-14. MRI depicting extension of Wilms tumor into the inferior vena cava.

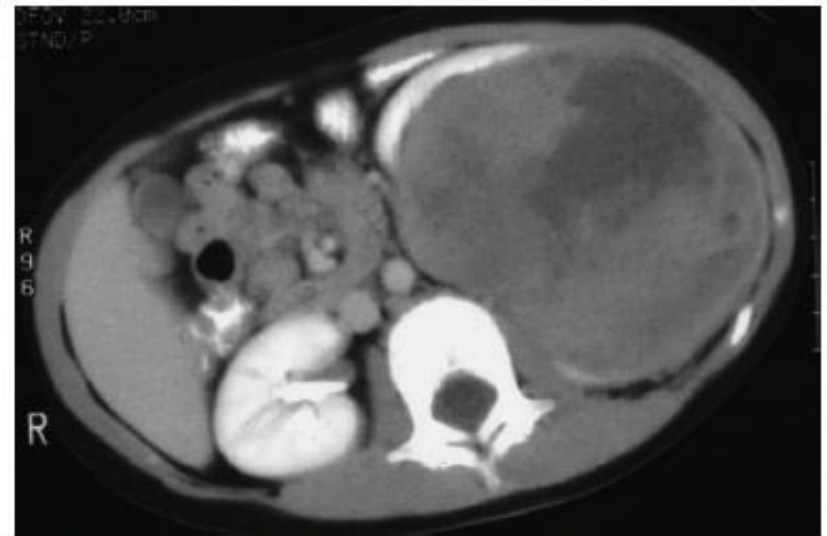

Figure 137-15. CT scan of a left Wilms tumor with a small rim of functioning renal parenchyma.



# Is there a need for exploration of the contralateral kidney??

- **The conclusion was that routine exploration is not necessary provided preoperative imaging with thin slices on multidetector helical CT scanners or MRI is performed.**
- A review of NWTs-4 patients with bilateral Wilms tumor found that **7%** of lesions were missed preoperatively (Ritchey et al, 1995b)

# Staging

- The most important determinants of outcome in children with Wilms tumor are the **histopathology** and **tumor stage**.
- **Any tumor spill is now a criterion for stage III designation, due to the increased risk for local tumor recurrence**

**Table 137-8.**

### Staging System of the Children's Oncology Group

Stage I	Tumor confined to the kidney and completely resected. The renal capsule is intact and the tumor was not ruptured prior to removal. No renal sinus extension. There is no residual tumor.
Stage II	Extracapsular penetration, but is completely resected. Renal sinus extension or extrarenal vessels may contain tumor thrombus or be infiltrated by tumor.
Stage III	Residual nonhematogenous tumor confined to the abdomen: lymph node involvement, any tumor spillage, peritoneal implants, tumor beyond surgical margin either grossly or microscopically, or tumor not completely removed
Stage IV	Hematogenous metastases to lung, liver, bone, brain, etc.
Stage V	Bilateral renal involvement at diagnosis.

# Treatment

- The initial therapy for most children with Wilms tumor is **radical nephrectomy**. Nephrectomy should be done by a Transperitoneal approach.
- Thorough exploration of the abdominal cavity is necessary to exclude local tumor extension, liver and nodal metastases, or peritoneal seeding.
- The renal vein and IVC are palpated to exclude intravascular tumor extension prior to vessel ligation.
- **Selective sampling** of suspicious nodes is an essential component of local tumor staging. Formal retroperitoneal lymph node dissection is not recommended.

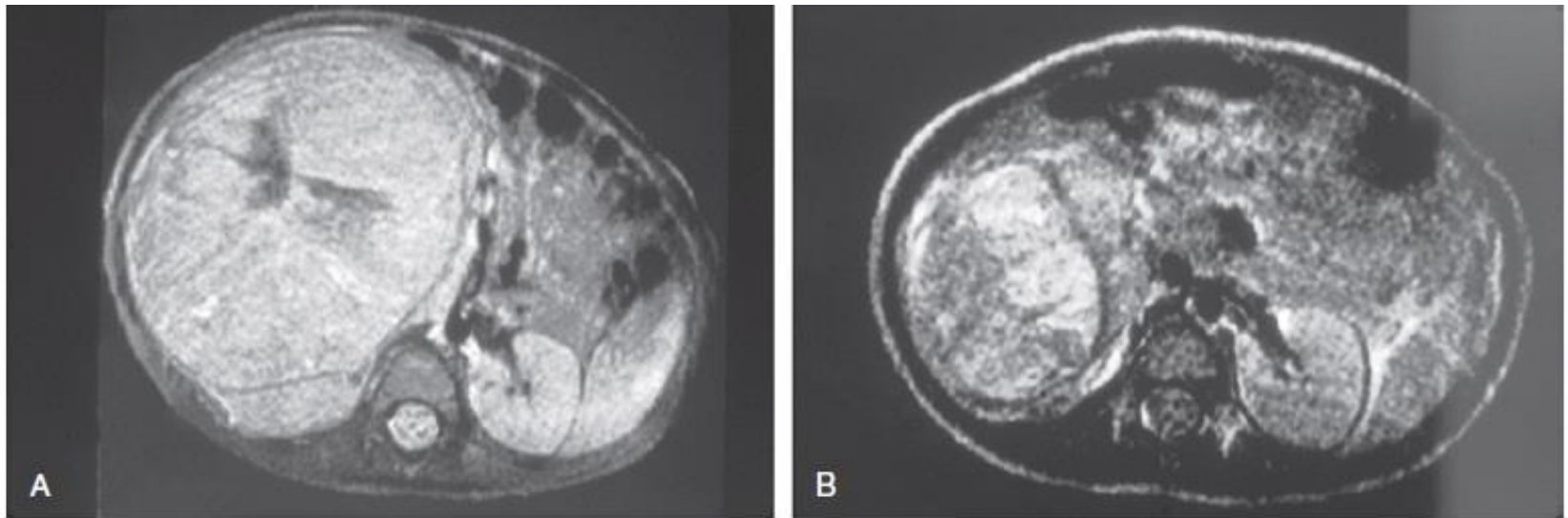
- **risk factors for local tumor recurrence**
  - **Tumor spillage**
  - **unfavorable histology**
  - **incomplete tumor removal**
  - **absence of any lymph node sampling.**
    - **The 2-year survival after abdominal recurrence was 43%, emphasizing the importance of the surgeon in performing careful and complete tumor resection.**
      - (Shamberger et al, 1999)

# Approach?

- National Wilms Tumor Study Group (NWTSG) in North America
- the International Society of Paediatric Oncology (SIOP), mainly in European countries.
  - Significant differences in guidelines however, overall survival rates are no different for patients treated using the NWTSG and SIOP approaches.

# International Society of Paediatric Oncology (SIOP)

- Neoadjuvant chemotherapy
  - Tumor shrinkage
  - reducing the risk of intraoperative rupture or spillage
  - Decrease morbidity by omitting XRT ex.post-chemotherapy stage I



**Figure 137-16.** **A**, MRI of a Wilms tumor that was pretreated with chemotherapy. **B**, After 6 weeks of chemotherapy, the tumor is much smaller in size.



# National Wilms Tumor Study Group (NWTSG)

- Surgery followed by Chemotherapy

# Bilateral Wilms Tumors

- 5% to 7% of children with Wilms
- Preoperative chemotherapy with the goal of tumor shrinkage
- Renal-sparing nephrectomy.

# Neuroblastoma

# Neuroblastoma

- Arise from cells of the **neural crest** that form the adrenal medulla and sympathetic ganglia.
- Tumors may occur anywhere along the sympathetic chain within the neck, thorax, retroperitoneum, or pelvis, or in the adrenal gland.
- 75% arise in the retroperitoneum, 50% in the adrenal, and 25% in the paravertebral ganglia.
- wide range of clinical presentations
- Can undergo spontaneous regression, differentiate to benign neoplasms, or exhibit extremely malignant behavior.

# Neuroblastoma

- Neuroblastoma accounts for 8% to 10% of all childhood cancers.
- It is the most common malignant tumor of infancy.
- peak incidence is 2 years of age

- Amplification of the *N-MYC oncogene* seen in roughly 20% of primary tumors is an adverse prognostic indicator
- Children 1 year old or younger have a better survival rate than older children.

- 20% of patients with familial neuroblastoma have bilateral
- adrenal or multifocal primary tumors, which are quite unusual in spontaneous cases.

# Presentation

- Asymptomatic abdominal mass. may cross the midline
- Abdominal pain
- Signs of metastatic disease. **70% of patients at diagnosis**
  - Pain from the tumor mass or from bony metastases.
  - Proptosis and periorbital ecchymosis → retrobulbar metastasis.
  - Compression the spinal cord, causing muscle weakness or sensory changes.
  - Catecholamine release may mimic symptoms seen in pheochromocytoma: paroxysmal hypertension, palpitations, flushing, and headache.
  - Vasoactive intestinal peptide → severe watery diarrhea and hypokalemia
  - Paraneoplastic neurologic findings, including cerebellar ataxia or myoclonus.



# Labs

- Metabolites of catecholamines, Vanillylmandelic acid (VMA) and homovanillic acid (HVA), are found in 90% to 95% of patients.
- Anemia.
- Bone marrow aspirate and biopsy.

# Imaging

- CT or MRI
- Bone scan
- Meta-iodobenzylguanidine (MIBG) scans for staging

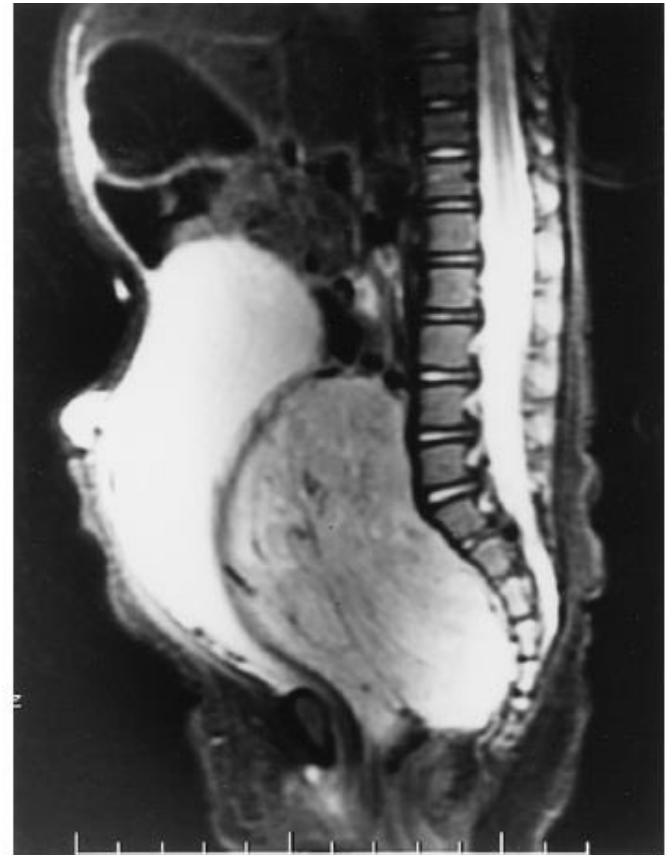

Figure 137-3. MRI demonstrating compression of bowel and bladder by a pelvic neuroblastoma.

# The International Neuroblastoma Staging System (INSS)

- Clinical, radiographic, and surgical evaluation of children with neuroblastoma

Table 137-1.

International Neuroblastoma Staging System

STAGE	DEFINITION
1	Localized tumor with complete gross excision, with or without microscopic residual disease; representative ipsilateral lymph nodes negative for tumor microscopically (nodes attached to and removed with the primary tumor may be positive).
2A	Localized tumor with incomplete gross excision; representative ipsilateral nonadherent lymph nodes negative for tumor microscopically.
2B	Localized tumor with or without complete gross excision, with ipsilateral nonadherent lymph nodes positive for tumor; enlarged contralateral lymph nodes must be negative microscopically.
3	Unresectable unilateral tumor infiltrating across the midline,* with or without regional lymph node involvement; or localized unilateral tumor with contralateral regional lymph node involvement; or midline tumor with bilateral extension by infiltration (unresectable) or by lymph node involvement.
4	Any primary tumor with dissemination to distant lymph nodes, bone, bone marrow, liver, skin, and/or other organs.
4S	Localized primary tumor (as defined for stage 1, 2A, or 2B), with dissemination limited to skin, liver, and/or bone marrow (less than 10% tumor) in infants less than 1 year of age.

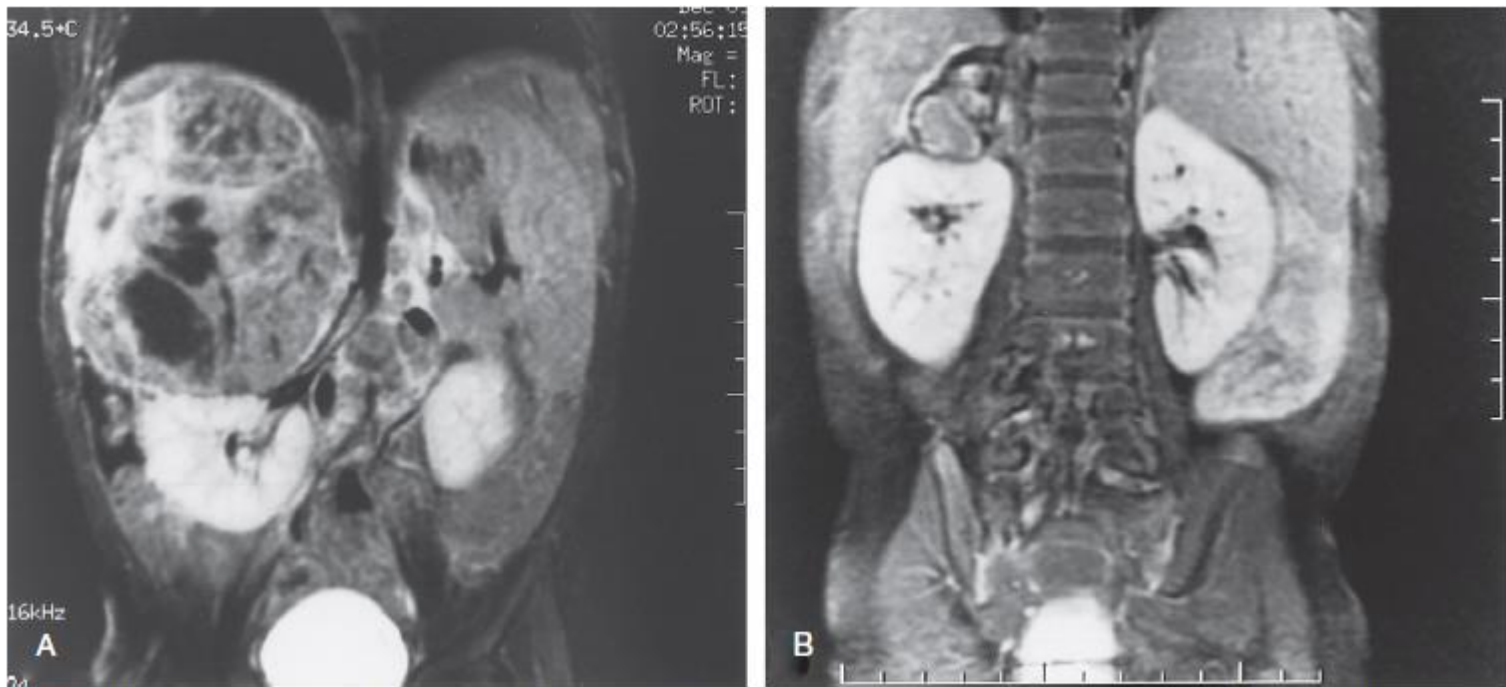\*The midline is defined as the vertebral column. Tumors originating on one side and crossing the midline must infiltrate to or beyond the opposite side of the vertebral column.

# Treatment

- The treatment modalities primarily used in the management of neuroblastoma are **surgery**, **chemotherapy**, and **radiation** therapy.
- The goals of surgery are to establish the diagnosis, stage the tumor, excise the tumor (if localized), and provide tissue for biologic studies.
  - Children with stage I neuroblastoma have a disease-free survival rate of greater than 90% with surgical excision alone (O'Neil et al, 1985; Nitschke et al, 1988; DeBernardi et al, 1995). Chemotherapy is indicated only in the event of recurrence unless the child has *N-MYC amplification and unfavorable* histology

# Chemotherapy

Advanced stage



**Figure 137-5.** MRI before and after chemotherapy, showing marked reduction in size of right suprarenal neuroblastoma. **A,** Before chemotherapy. **B,** After chemotherapy.

- Radiotherapy increased local control in children with advanced **stage IV or bulky stage III** tumors (Matthay et al, 1989; Castleberry 1991; Evans et al, 1996)

